



**Southern
Cross Dental**

Great care. Great practice.

SCD CASE STUDY

Attachments in Prosthodontics

Precision attachments are retention units milled out of alloy. They have male and female parts that fit together with tolerances of 10 microns.

It is important to consult with the patient about the cost of using precision attachments in both fixed and removable prosthodontics. The patient needs to understand the inherent added costs of crown work required for these cases.

Precision Attachments Can Be Divided Into the Following Main Groups:

Intracoronal

These are mainly used in connecting units of fixed partial prostheses and to retain removable prostheses with distal extension or bounded saddles.

They are purchased as a finished product and are soldered or cast to the final prosthesis. They are incorporated within the contours of the crown and direct the forces of occlusion down the long axis of the tooth. Their rigidity allows the prosthesis to transfer most of the occlusal force to the teeth in which the attachments are incorporated, and less to the tissuebearing areas.

Extracoronal

This type of attachment provides stability and retention for removable distal extension prostheses. Extracoronal attachments are positioned entirely outside the crown contour of the tooth. The advantages of this type of attachment are the normal tooth contour can be maintained, minimal tooth reduction is necessary and the possibility of devitalising the tooth is reduced. Also, the path of insertion is easier for patients with limited dexterity. It is more difficult to maintain hygiene with extracoronal attachments and patients need to be instructed on the use of hygiene accessories such as proxabrushes etc. Keeping the underside of the attachment area clean is essential for a healthy tissue response in the area.

Studs

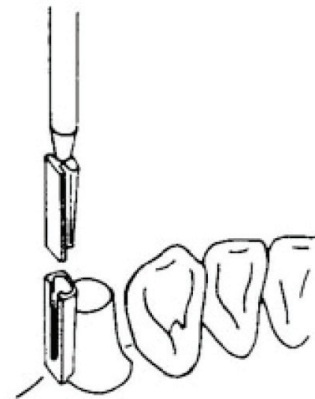
These are usually in the form of a ball and socket. This attachment serves mainly for overdenture stabilisation and retention of the prosthesis.

Bars

Bars usually splint groups of teeth and are currently used for overdenture retention and stabilisation.

Attachment Types

- Prefabricated by the manufacturer - usually made of precious metal.
- Plastic attachments (castable) - simple, precise and indicated for fixed bridges and removable dentures.



What is an intracoronal attachment?

Intracoronal attachments are incorporated entirely within the contour of the crown. To do this, the tooth needs to be restored with a full or partial coverage crown in either gold or porcelain-fused-to-metal. The female component is incorporated in the crown and the male component (patrix) in the prosthesis.

Intracoronal attachments are non-resilient. They may need double abutting or splinting of the adjacent teeth. This form of attachment offers indirect retention and a more precise path of placement. The 3D size of the tooth will be a predictor of the functional or biomechanical success with this attachment (Makkar, S., et al., 2011). A clinical crown of more than 4mm is needed with a similar buccolingual width (Feinberg, E., 1982).

Indications for attachments

Dental attachments can be used in treatment planning all aspects of dentistry because they provide cosmetic and functional alternative adjuncts to traditional prosthetic approaches. The indications for using attachments are as follows:

1. Movable joint in fixed movable bridgework.
2. As stress breaker in free-end saddles and bridges.
3. Retainers for aesthetically critical removable partial dentures where clasps do not want to be visible.
4. As a connector for sectional dentures.

Contraindications

1. Inadequate dexterity skills of patient.
2. Poor oral hygiene.
3. Abnormally high caries rate.
4. Inadequate space to use (Teeth that are very narrow buccolingually).
5. Structurally weak abutment teeth.
6. Non-parallel abutments where crowns will need to be too bulky to allow a parallel path of insertion.

Advantages

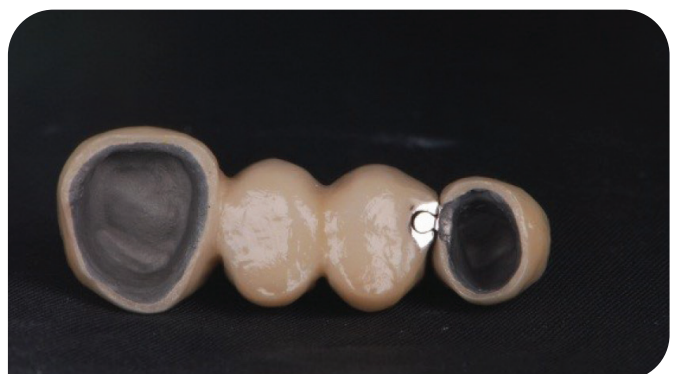
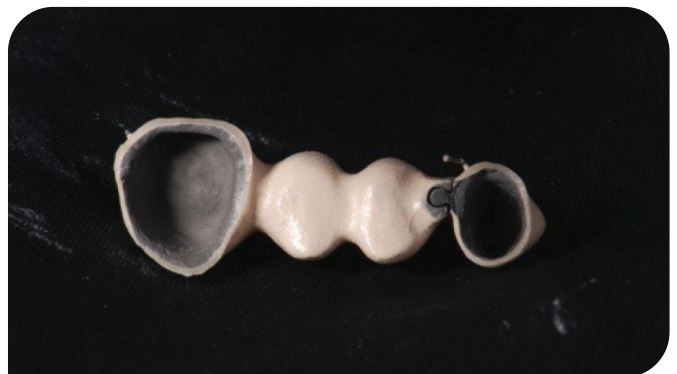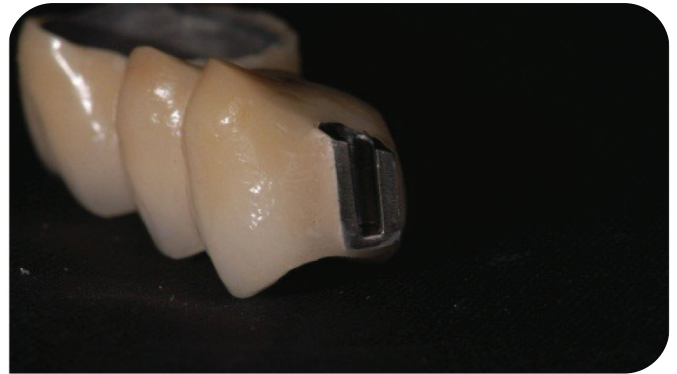
1. Aesthetics - labial or buccal clasp arm can be eliminated completely along with rests.
2. Reduced stress on the abutment teeth compared to conventional clasps.
3. All stress is directed along the long axis of the tooth.
4. Avoidance of wear on abutment porcelain or enamel.
5. Reduced risk of dislodgement of crown from retentive unit (compared to conventional clasps).

Disadvantages

1. Tooth may have to be extensively cut to provide enough space to accommodate an intracoronal attachment.
2. A bulge in the crown is usually created by incorporation of an intracoronal attachment.
3. The attachment is subject to wear as a result of friction between metal parts.
4. As wear occurs, the male portion fits more loosely thus allowing excessive movement and threat of injury to abutment teeth, as well as a reduction in overall retention over time.

If it is not possible to create a box preparation that will totally incorporate the female element, then an extracoronal attachment should be considered. These attachments are non-resilient. When limited

space exists, a milled lingual surface should be provided on the crown. Most wear occurs on these attachments during placement and removal.



Case Report

The dentist was approached by a patient for fixed replacement of the missing teeth in the upper right quadrant. Implants or a removable appliance were discussed as options but were rejected.

Technique

Preliminary impressions were made and the casts mounted on a semi-adjustable articulator with the pre-established vertical dimension.

A diagnostic wax-up was completed and the bridge designed. A putty matrix of the completed diagnostic wax-up was made to evaluate the existing space for the intracoronal attachment. A special tray was made for final impressions.

Maxillary teeth were prepared and the teeth temporised. After articulation, the teeth were waxed-up. Parallelism was obtained with the milling tool attached to the surveyor. A mandrel was used on the surveyor to place the attachments in the wax patterns of the crowns with a common path of insertion.

An extracoronal attachment was incorporated in the distal surface of the PFM crown on tooth 13. The crowns were fabricated and veneered. The case was returned to the dentist for fit, aesthetic and occlusal checking. Cementation followed.

Continual periodic follow up to monitor the function and maintenance of the bridge was done.

Southern Cross Dental would like to thank Dr Tom Lind, Kogarah, Sydney NSW Australia for his contribution to this article.

References

Attachments and Implants reference manual 6th edition source: Removable Partial Denture Design by Krol et al Fourth Edition

Feinberg, E., 1982. Diagnosing and prescribing

therapeutic attachment-retained partial dentures. The New York State Dental Journal, 48(1), p.27.

Makkar, S., Chhabra, A. and Khare, A., 2011. Attachment retained removable partial denture: A Clinical Report. International Journal of Clinical Dental Science, 2(2).

Peter E. Staubli, MDT, CDT. Attachments & Implants Reference Manual, 6th Ed. Implant Dentistry. 7(4):377, 1998.

Shetty, N.B., Shetty, S., Nagaraj, E., Shetty, O. and D'souza, R., 2014. Precision attachments for aesthetics and function: a case report. Journal of clinical and diagnostic research: JCDR, 8(1), p.268.