



**Southern  
Cross Dental**

Great care. Great practice.

# SCD CASE STUDY

## Minimal Intervention Dentistry – The Penn Composite Stent™

The Penn Composite Stent™ is a treatment technique following the principles of Minimal Intervention Dentistry.

### **What is Minimal Intervention Dentistry?**

- Aims to provide treatment options with minimal loss of natural teeth ie. at minimal
- biological cost (Penn Composite Stent™)
- Bleaching and orthodontic therapy – “Invisalign®”
- Removable orthodontic appliances
- Aesthetic recontouring
- Treatment of Neuromuscular Disorders and Obstructive Sleep Apnoea

### **What is a Penn Composite Stent™?**

- The Penn Composite Stent™ technique enables the dentist to conservatively build-up teeth with traditional etching techniques and composite resin in a customised form for any worn areas of teeth
- Can be adapted to anterior and posterior regions
- Can be used for aesthetic cases as well as functional reconstructions
- Can be modified at any stage

## Advantages of Penn Composite Stent™

- Ultra-conservative
- Convenient delivery
- Very pleasing anatomy achievable
- Patient can see shape pre-operatively
- Extremely cost-effective
- Reversible
- Complements Invisalign® to complete aesthetic process with “minimal intervention”
- Repairs simple and inexpensive
- No temporary restorations usually
  - note that there are times when temporisation may be required:
    - » Restore defective lesions
    - » Interim restorative plan – eg. Penn Composite Stent™ and lab-made provisionals and use of nightly stents with CPP-ACP
- No anaesthetic
- No dentinal sensitivity

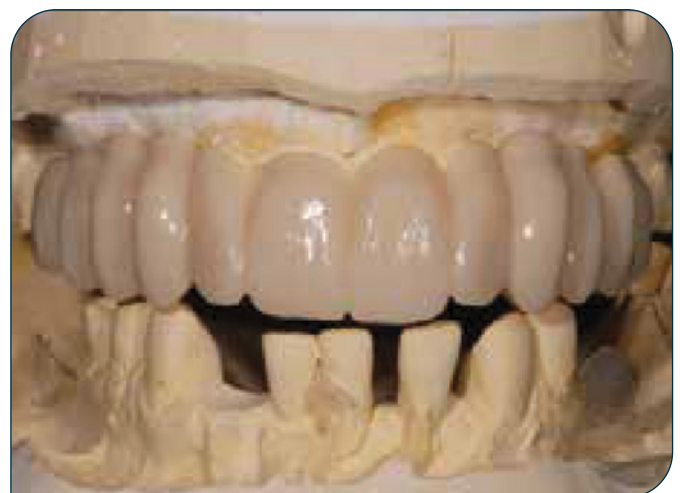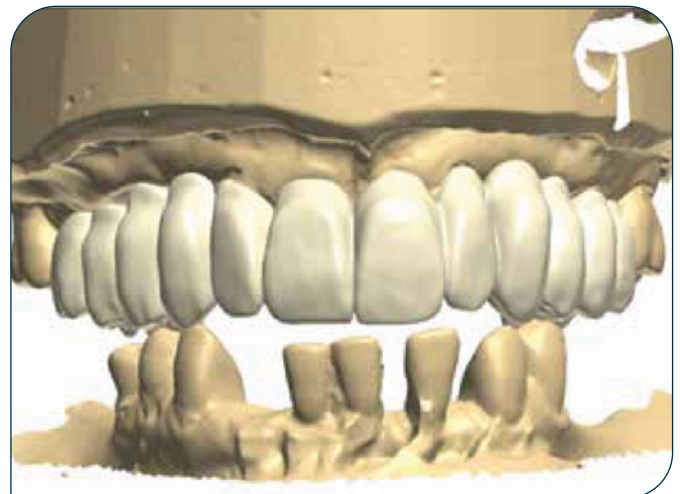
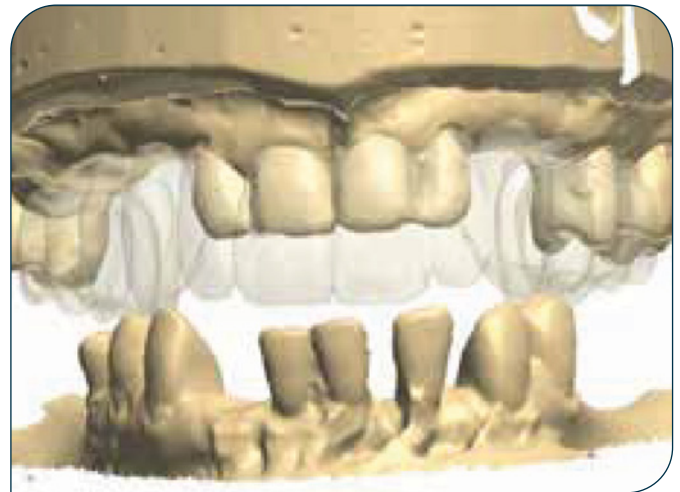
## Disadvantages of Penn Composite Stent™

- Composite will wear down
- Composite will stain
- Aesthetics not quite as striking as ceramic veneers – translucency/gloss/vitality
- Chipping

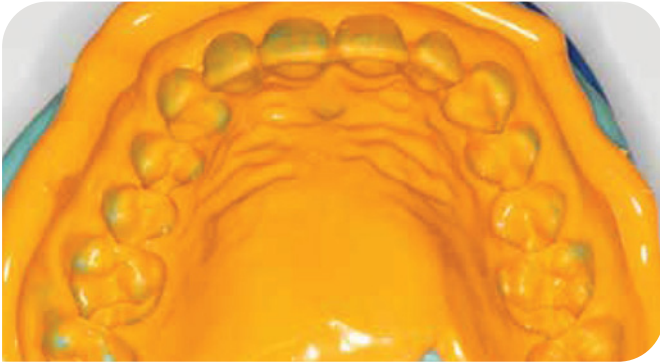
## Case Presentation

- “The correct presentation of a treatment plan is an essential component of fostering a good dentist-patient relationship” (Bain CA, 2004)
- Should occur preferably in office/consultation room rather than treatment clinic
- Employ digital x-rays and digital photography
- Pre-treatment study models and diagnostic wax-ups should be well trimmed and mounted on an articulator
- Outline life-expectancy and maintenance

## Virtual Possibilities



**Provisionals from Digital Diagnostic Wax-ups**



### Impression Taking

- Arch recorded completely in light body
- Check 2nd molars - axial and distal walls

### Communicate with your laboratory

- Good clinical photographic records will help the laboratory with stent cases
- Supply a portrait of retracted, anterior and posterior and occlusal views
- Check facial shape, balance, smile lines, lip profile and verify the midline

### Smile Designs

These are assigned by:

- Personality characteristics - eg. aggressive and dominant
- Age (mature or youthful)
- Overall impression (Hollywood or natural)
- What the patient requests

### Vital Elements Of Smile Design

Tooth components:

- Dental midline
- Incisal lengths
- Tooth dimensions
- Axial inclinations
- Zenith points - zenith points are the most apical position of the cervical tooth margin where the gingiva is most scalloped

**NB.** Overlapping teeth wreak havoc with interproximal lines and shapes. Trim imbricated areas of the tooth to allow for strips to be straight and correct mesio distal diameters. Cause limitations on stent use.

### Soft tissue components:

- Gingival health
- Gingival levels and harmony
- Interdental embrasure
- Smile line

### Interdental contact area and point:

- Gingival embrasure
- Sex, personality and age
- Symmetry and balance

### Wax-up approval process

This is essential for the dentist to review and then discuss with the patient.

### Case Selection

- Before and After booklets and slideshows will increase understanding and motivation
- Web based 'smile' galleries demonstrating treatments you offer in your surgery
- Dental, medical records and photographs are extremely helpful when referring cases

### Essential Preparation

- Periodontal work-up
- Pre-bleaching (Bond strengths to bleached enamel are significantly lower immediately after bleaching with 35% hydrogen peroxide. Strengths are restored after 7 days. Sundfeld et al., 2005)
- Replace leaky restorations
- Reconstitute palatal aspects of anteriors
- Photographic records
- Interproximal reduction (very slight) may be required for interproximal strips to be easily placed

### Preparation for Resin Build-up

- Remove old bonding
- Prophyl: clean teeth with pumice and water
- Shade selection
- Before isolation - select shade using shade guide
- Teeth are NOT monochromatic. Divide tooth into 3 regions
- Gingival area – gingival area will have various amounts of yellow
- Body area – body of tooth may consist of shade

- of grey, yellow or brown
- Incisal area – incisal edges may contain a blue or grey colour. Consider adjacent teeth
- Restoration depth: colour restoration exhibits is affected by its thickness. Match shade from the part of the shade guide similar to the thickness of the restoration
- Mock-up
- Apply chosen shade on unetched tooth
- Evaluate shade under different lights

## Materials

Controlled fluidity is essential.

Composites used should inject like a flowable and stack like a traditional composite.

### New Generation Composites

- Premise™ Flowable (Kerr)
- CLEARFIL MAJESTY Flow™ (Kuraray)
- CLEARFIL MAJESTY ES-2 (Kuraray)
- Filtek™ Supreme Ultra 3M ESPE
- Beautifil Flow Plus
- G-aenial® Universal Flo

### Finishing the Restoration

Finishing and polishing can be done with:

- Series of carbide finishing burs (Q-Finishers [KOMET USA])
- Sandpaper discs (Sof-Lex Finishing and Polishing Discs [3M ESPE]), coarse, medium, fine and superfine
- Composite polishing paste (Enamelise Polishing Paste - Cosmedent) on a felt disc

[www.cosmedent.com](http://www.cosmedent.com)

## Case Report

**Initial telephone call from Dentist:** I'm in the process of working out a treatment plan for a full mouth rehab. I would like to have a look at using the Penn Composite Stent™ for 8 upper teeth and 4 lower teeth. The treatment would involve opening the bite and also 3 crowns and 4 direct composites. I have articulated study models. What would be the next step?

**SCD Technical Team:** We can do a wax up at the opened dimension and once approved, can duplicate the model and make the stents. So if you send the models and either the opened up bite or tell us how far to open on the articulator, we can go from there.

**Dentist:** Patient will be ready to proceed in a few months. I will organise things over the next few months and let you know when to expect the impressions/models. I will be sending the study models, for your appraisal. The study models are marked: -

**FMZir** - indirect crown

**D** - direct composite

**S** - stent formed composite

### This is the plan:

1. Diagnostic wax up for full mouth rehab - opening the bite 3-4mm - I'm planning that there will be 20 teeth to build up when we open the bite, with 3 indirect crowns (tooth 15,26,47) and 17 direct composites - 5 of those I will place freehand (teeth 16,27,34,44,45) and 12 with a stent.
2. 2 x suckdown for a temporary direct resin overlay.
3. 2 x Penn Composite Stent™ (Penn Stent) for 8 upper teeth (13-25) and 4 lower teeth (32 42) to replace the direct overlay in sections.
4. Maxillary occlusal splint to protect the teeth at the end of reconstruction.

### SCD Technical Team advised:

The models were received and articulated on an articulator.

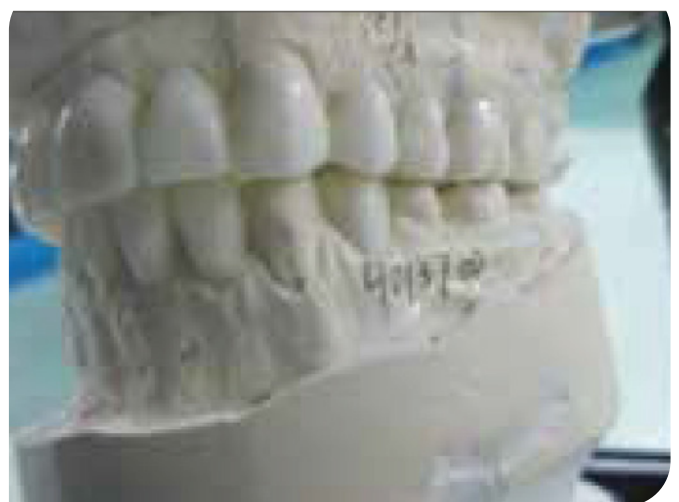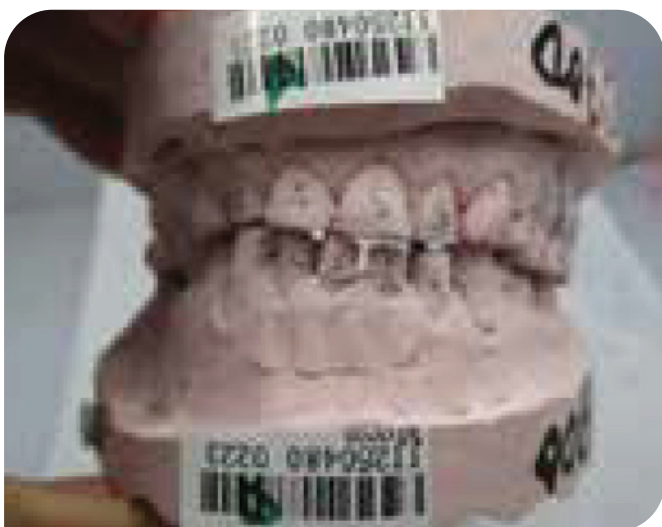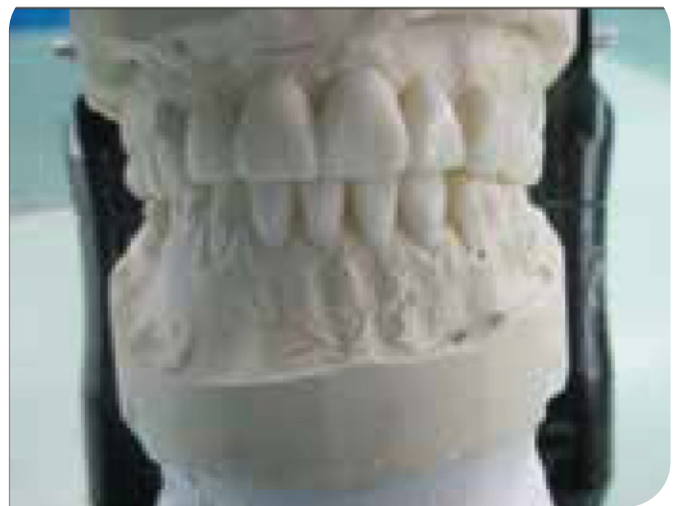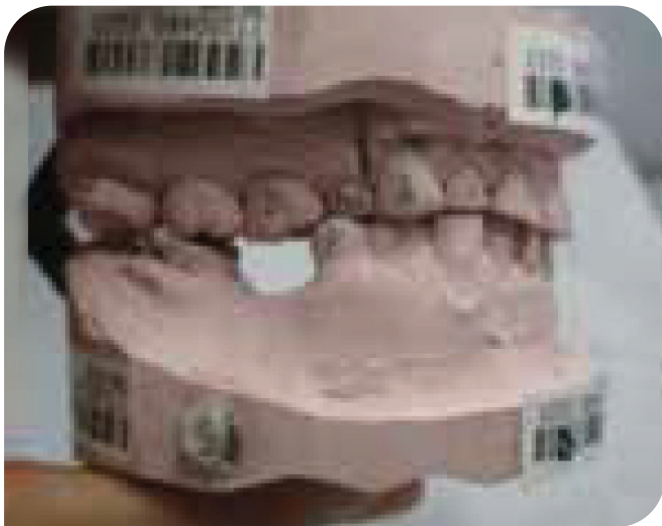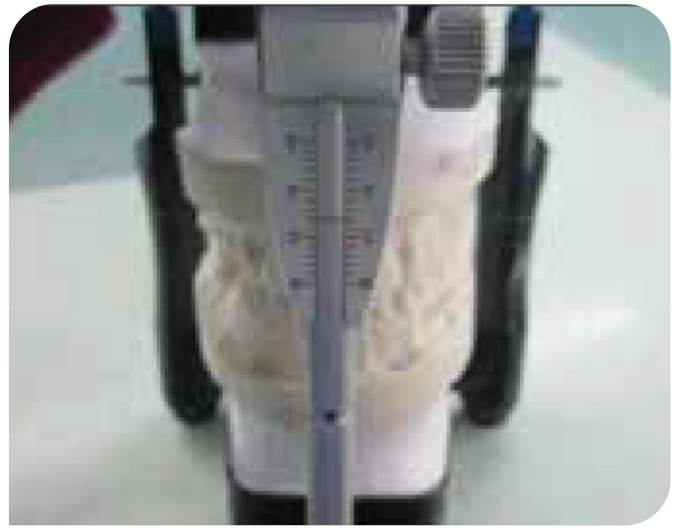Photos of articulated models.

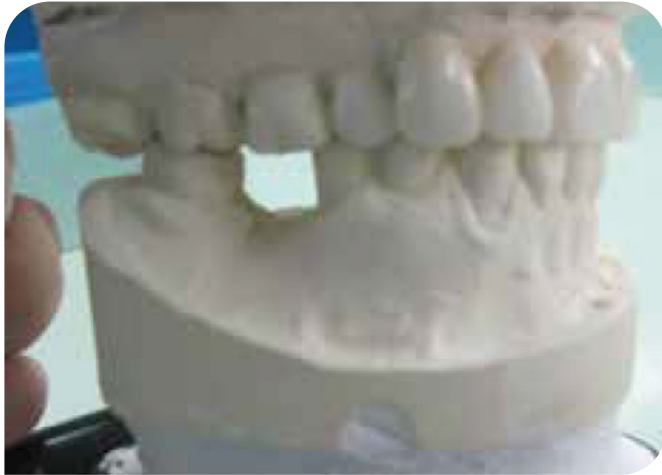Photos after doing the wax-up at 3-4mm open VDO.

### Existing vertical dimension



### Increased vertical dimension



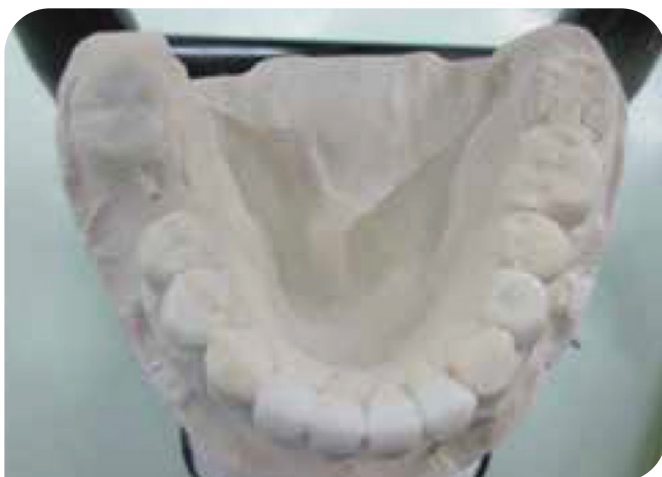
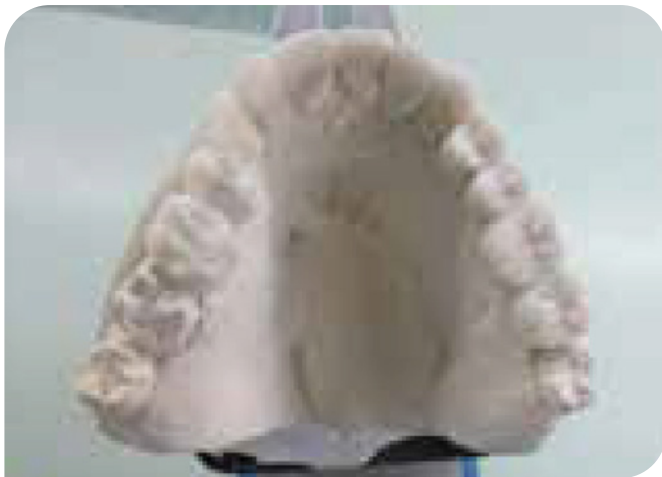
## BIBLIOGRAPHY

Bain, C.A., 2004. Treatment planning in general dental practice: case presentation and communicating with the patient. *Dental update*, 31(2), pp.72-6.

“Effect of Time Interval between Bleaching and Bonding on Tag Formation”

Sundfeld, Briso et al, *Bulletin Tokyo Dent. Coll.* 2005 Feb; 46(1-2): 1-6.



The patient elected to proceed with the treatment plan based on the case presentation appointment. The patient understood the implications of both non-treatment and the proposed treatment.